

BRIGHAM HEALTH



BRIGHAM AND
WOMEN'S HOSPITAL

BRIGHAM AND
WOMEN'S HOSPITAL

Thomas L. Carroll, MD
Director, BWH Program for Voice, Swallowing
and Upper Airway Health

Lindsey Lambert Gordon, MS, CCC-SLP
Senior Speech Pathologist

Upper Airway Noise: Laryngeal Disordered Breathing



HARVARD MEDICAL SCHOOL
TEACHING HOSPITAL



Mass General Brigham

Disclosures

Thomas Carroll, MD

- Sofregen Medical and N-Zyme Medical
 - Tock options, Advisory board
- Pentax Medical, GSK, Ambu
 - Consultant
- Plural Publishing
 - Royalties for book, *Chronic Cough*

Lindsey Gordon, MS, CCC-SLP

- None

The ILO VCD Toolkit

- Resource for everything regarding laryngeal disordered breathing.

<https://ilovcdtoolkit.org/>

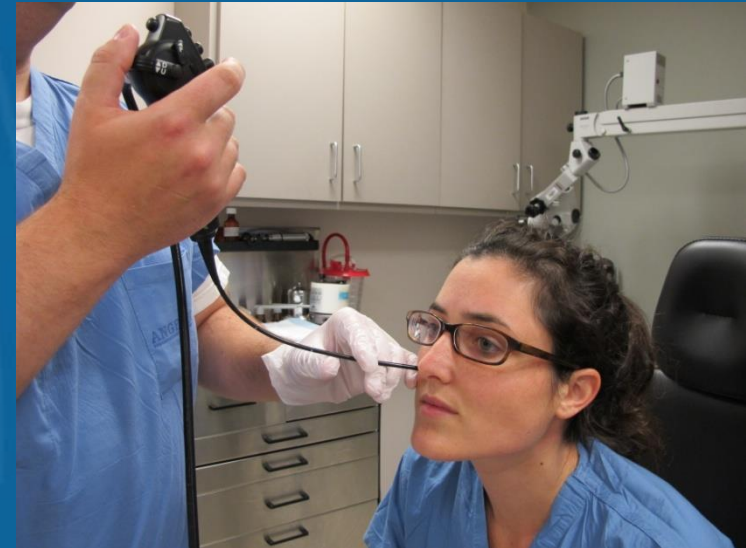Upper airway Sx:

Chronic Cough and Dyspnea

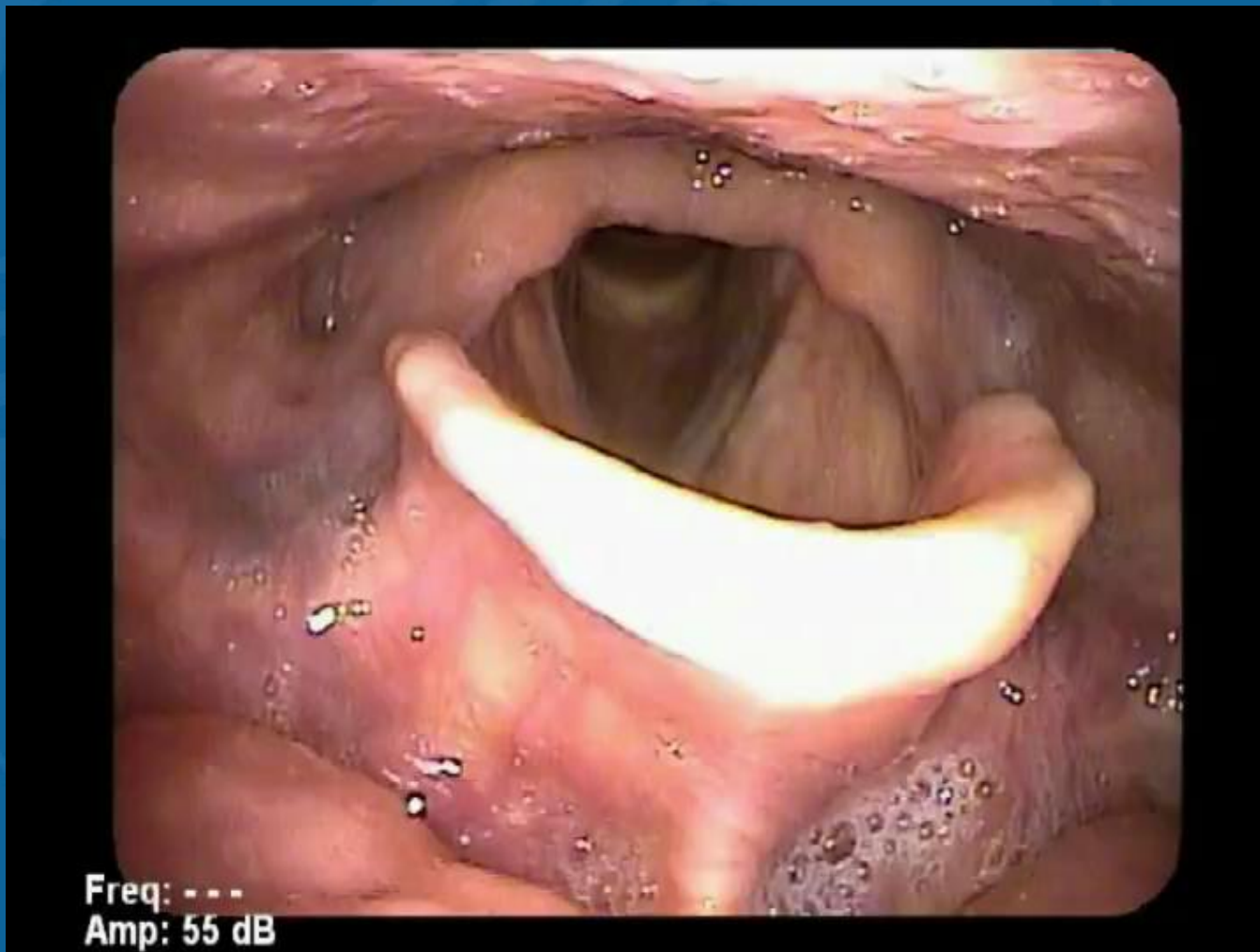
- Dyspnea
 - Glottic and subglottic Stenosis: biphasic stridor
 - Listen over chest and then neck (neck is louder)
 - Inducible Laryngeal Obstruction(ILO)
 - Formerly Paradoxical Vocal Fold Motion Disorder (PVFM) or Vocal cord dysfunction (VCD)
 - Inspiratory Stridor
 - Approximately 1/3 of all ILO patients are first given diagnosis of asthma
 - » Morris MJ, Allan PF and Perkins PJ . Vocal cord dysfunction: etiologies and treatment. Clin Pulm Med, 13 (2) (2006), 73-86
 - Possibly reflux related
- Chronic Cough (beyond allergies and true asthma)
 - Reflux
 - Silent, non-acid vs. acid, chronic
 - Glottic Insufficiency
 - Gross or subtle loss of air inappropriately during phonation
 - Post viral vagal neuropathy (PVVN)

Evaluating the larynx

- Flexible Chip Tip Laryngoscopes
 - Observe patient position
 - High-definition Flexible scope (1080p)
 - Rigid stroboscopy
 - Halogen and stroboscopy
- Light filters for vessels and lesions
- Recording ability for comparison
- Server based storage



Normal Laryngeal Exam: Neurolaryngeal and Stroboscopy



- Adduct with phonation
- Abduct with respiration
- Stretch with pitch increase
- Rapid alternating movement
- Connected speech
- Vibration and mucosal wave

Inducible Laryngeal Obstruction (ILO)

- **Inappropriate adduction or closure of the true vocal folds**
 - Primarily on inspiration, less often expiration
- Also called:
 - Vocal Cord Dysfunction (VCD)
 - Paradoxical vocal fold motion
 - Episodic paroxysmal laryngospasm
 - Factitious asthma
 - Munchausen's stridor
 - Psychogenic stridor
 - Episodic laryngeal dyskinesia
 - Adductor laryngeal breathing dystonia
- May result in upper airway obstruction and laryngeal stridor, cough
- Often misdiagnosed as asthma
- E-ILO—Exercise-Induced ILO

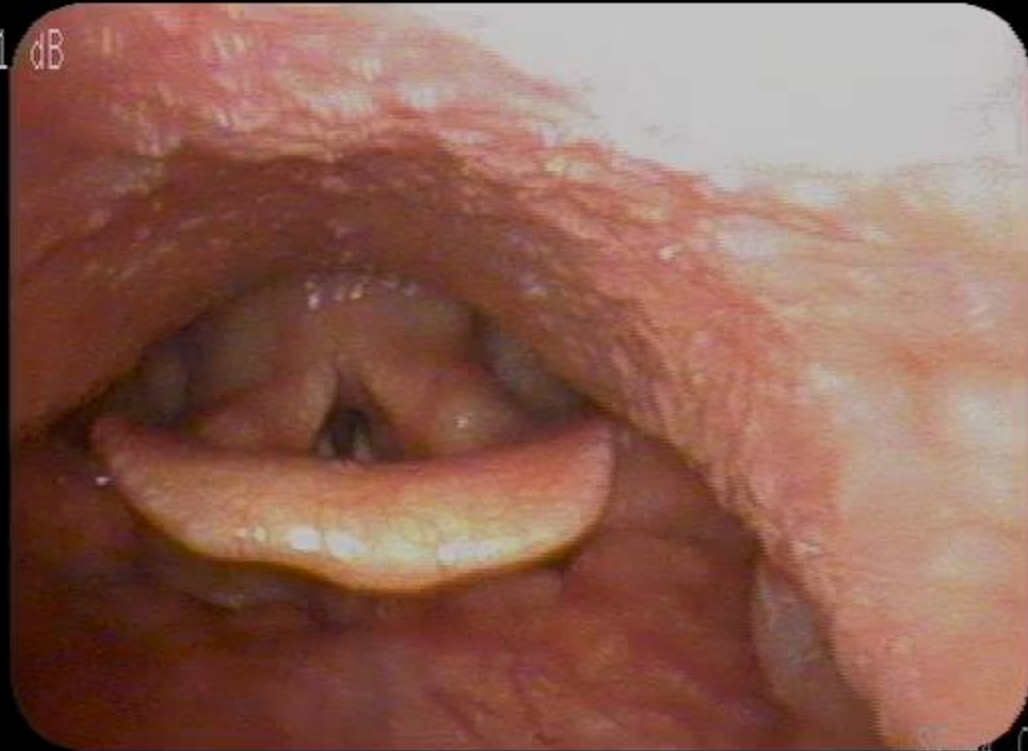Leong P, Vertigan AE, Hew M, Baxter M, Phyland D, Hull JH, et al.

Diagnosis of vocal cord dysfunction/inducible laryngeal obstruction: An International Delphi Consensus Study. Journal of Allergy and Clinical Immunology. 2023 Oct;152(4):899–906

ILO

FREQ: --- Hz

AMP: 61 dB



SE:14, CE:+2

ILO

- Males and females of all ages
- Mostly female
- Most patients are 10-40 years of age
- Documented in infants as young as one month
- Affects athletes
 - 5% prevalence of inspiratory stridor in elite Olympic athletes (*Rundell & Spiering, 2003*)
- LPR/GERD found in many ILO patients
- Dyspnea Index (DI) used to quantify and follow patient symptoms
 - Gartner-Schmidt JL, Shembel AC, Zullo TG, Rosen CA. Development and Validation of the Dyspnea Index (DI): A Severity Index for Upper Airway–Related Dyspnea. *Journal of Voice*. 2014;28(6):775-782.
 - De Guzman V, Ballif CL, Maurer R, Hartnick CJ, Raol N. Validation of the dyspnea index in adolescents with exercise-induced paradoxical vocal fold motion. *JAMA Otolaryngol Head Neck Surg*. 2014;140(9):823-828.

ILO

- Psychogenic etiology?
 - Previously believed to be the primary cause
 - Rarely in my experience
 - Typically due to inadequate non-acid reflux workup
 - Higher levels of anxiety seen in PVFMD patients
 - Probably DUE to PVFM, not other way around
 - If concern for underlying psych issue, refer to appropriate therapist
 - Association with conversion disorder in a significant subset of PFVMD patients

Husein O et al. Laryngoscope, 2008; 118

Dietrich M et al. J Voice, 2008; 22(4): 472-88

ILO

- Mechanism??
 - Laryngeal mucosa chemoreceptors
 - Trigger the protective reflex in response to fluid in the upper airway.
 - Reflux/Allergy/other
 - “Sensitizes” or maybe “desensitizes” the larynx
 - Cukier-Blaj et al. Laryngoscope, 2008; 118: 367-70
 - » Hyper efferent response in response to hyposensitive afferent receptors in patients with PVFMD
 - » Edema due to LPR causes decreased sensation
 - Trigger reflexive adduction of the vocal folds or supraglottic structures
 - Sensitized for other irritants

ILO vs. Asthma

	INSPIRATORY STRIDOR/PVFMD	ASTHMA/EIB
NOISE OCCURS DURING	Inhalation (stridor)	Exhalation (wheeze)
SOUND ORIGINATES IN	Neck	Chest
PATIENT REPORTS	Throat tightness	Chest tightness
SYMPTOMS WITH EXERCISE PEAK	Shortly after starting exercise and resolves within 5 min of exercise cessation	Between 5 and 20 min after exercise stops
β -AGONIST RESPONSE	No	Yes

Diagnosis

- Good Story/History
 - Respiratory irritants have been identified by patients as **triggers** for a PVFMD event
 - Perfume, Cigarette smoke, Gasoline, environmental triggers, Cold/Hot temperature change, Post prandial
 - Exercise induced
- Flow Loop If actively symptomatic
 - Blunting/sawtooth of inspiratory loop is suggestive
- Laryngeal exam at baseline
 - often see “twitchy Larynx” ...

Diagnosis of vocal cord dysfunction/inducible laryngeal obstruction: An International Delphi Consensus Study

Leong P, Vertigan AE, Hew M et al. Journal of Allergy and Clinical Immunology. 2023 Oct;152(4):899–906

- 47 international experts of multiple fields
- Modified 2-Round Delphi study
- >70% of experts in agreement in round 2 accepted statement
- 130 (65%) Statements met agreement on
- Results:
 - Laryngoscopy with provocation (safely) is the gold and interpretation after adequate provocation
 - >50% closure of vocal folds on inspiratory or expiratory ILO

ILO

- Further testing
 - Pulmonary and allergy workup typically precedes referral
 - Level 1 CPET with continuous laryngoscopy during exercise (CLE)
 - Gold standard for EILO
 - Evaluate laryngeal closing during patient symptoms
 - Laryngoscopy after dry air challenge
 - Evaluating larynx and lower airways in tandem with spirometry
 - Hypopharyngeal-esophageal multichannel intraluminal impedance and dual pH
 - HEMII-pH
 - Symptom correlation? (not typically)
 - High resolution esophageal manometry
 - Acid or Non-Acid reflux
 - Ineffective esophageal motility

Treatment of ILO

- Behavioral
 - Empowerment
 - Breath work
 - Cough / throat clearing avoidance
 - Carryover

Treatment of ILO

Breath work:

- Pursed lip exhalation FIRST
- Followed by short sniff inhalation
- Reflexive action that causes v.f to abduct fully
 - Decreases turbulence, less resistance
- Can be variants of both exhalation and inhalation depending on patient preference

Treatment of ILO

Cough/ Throat clearing Avoidance:

- Breathing sequence
- Hard swallow
- Silent, or whispered, throat clear

*all to avoid the sensation of mucus/irritation in throat
-analogy of bug bite – don't scratch the itch!

Exercise-induced Laryngeal Obstruction (EILO)

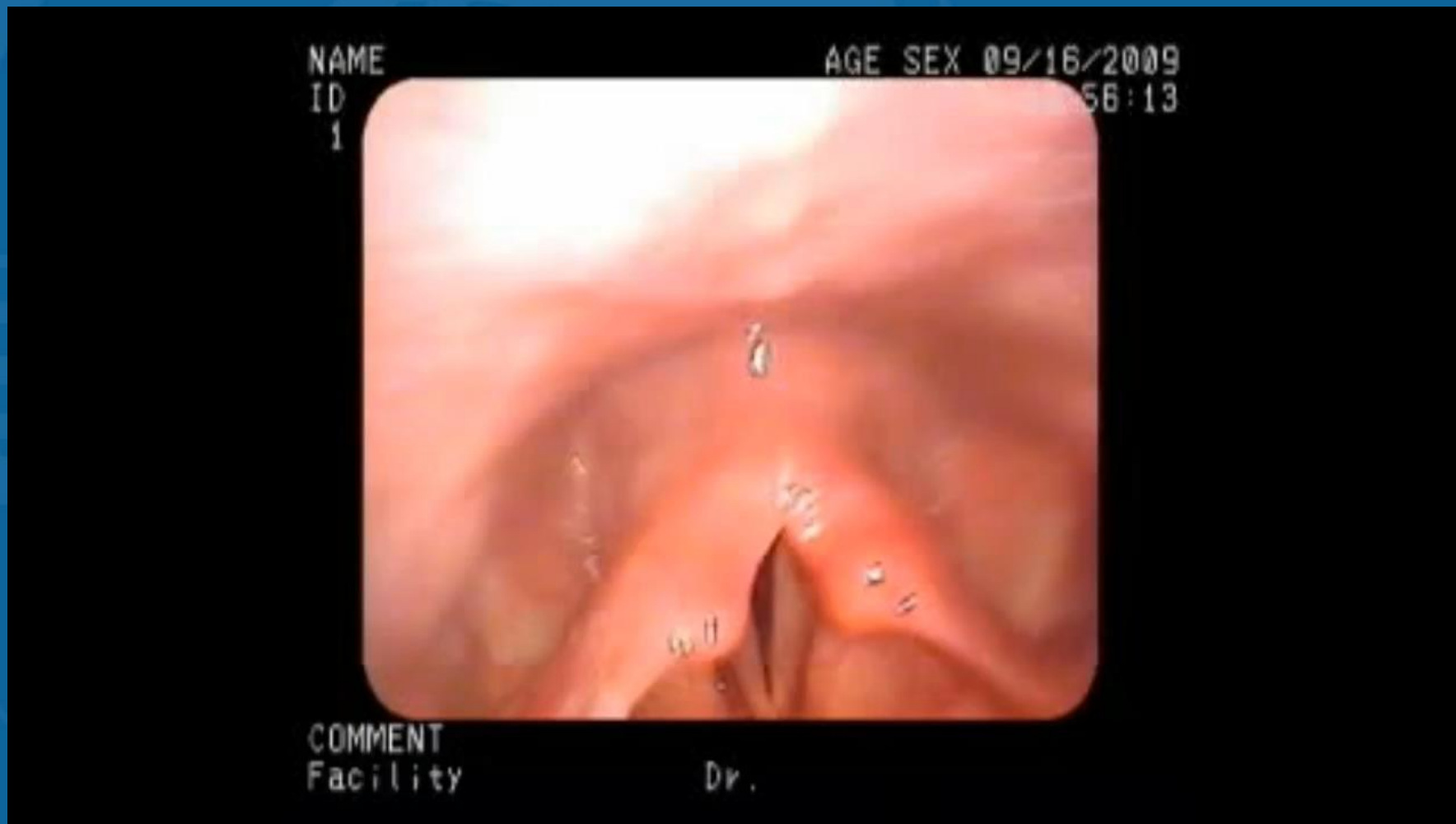
- Airway noise during inspiration
- Noise can originate from vocal folds, supraglottic structures
 - Arytenoid prolapse
 - Redundant arytenoid mucosa
 - epiglottic retraction
 - pharyngeal wall constriction
- Typically present during exercise and peak exertion
- ADL's typically not affected

EILO Treatment

- Establish abdominal breathing pattern
- Pursed lip inhalation/exhalation
- Olin Biphasic Inspiration technique
 - Two part inhale:
 - tooth/lip/tongue variant
 - open throat
 - Comfortable exhale or pursed lip exhale
 - To be completed every 'x' breath
- Open throat practice with awareness of throat tension
- Hierarchical practice coordinates breathing with movement
 - Sport specific modifications (swimming vs. running)
- Daily practice, several times a day

Johnston, K. et al Journal of Voice 2018

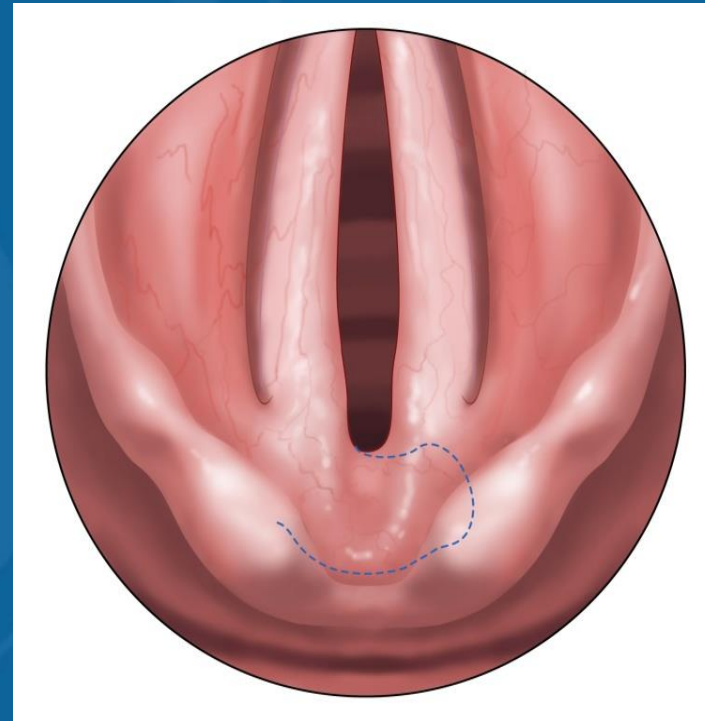
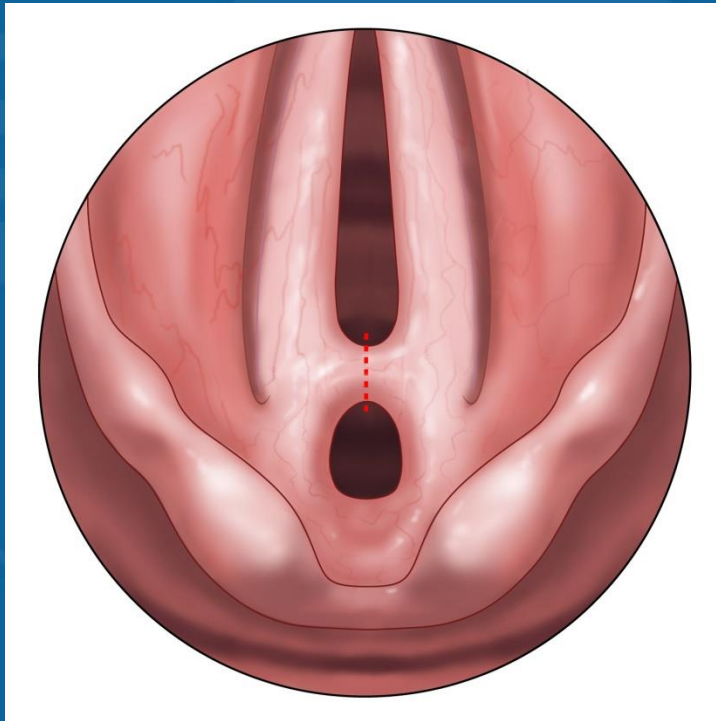
Treatment of EILO



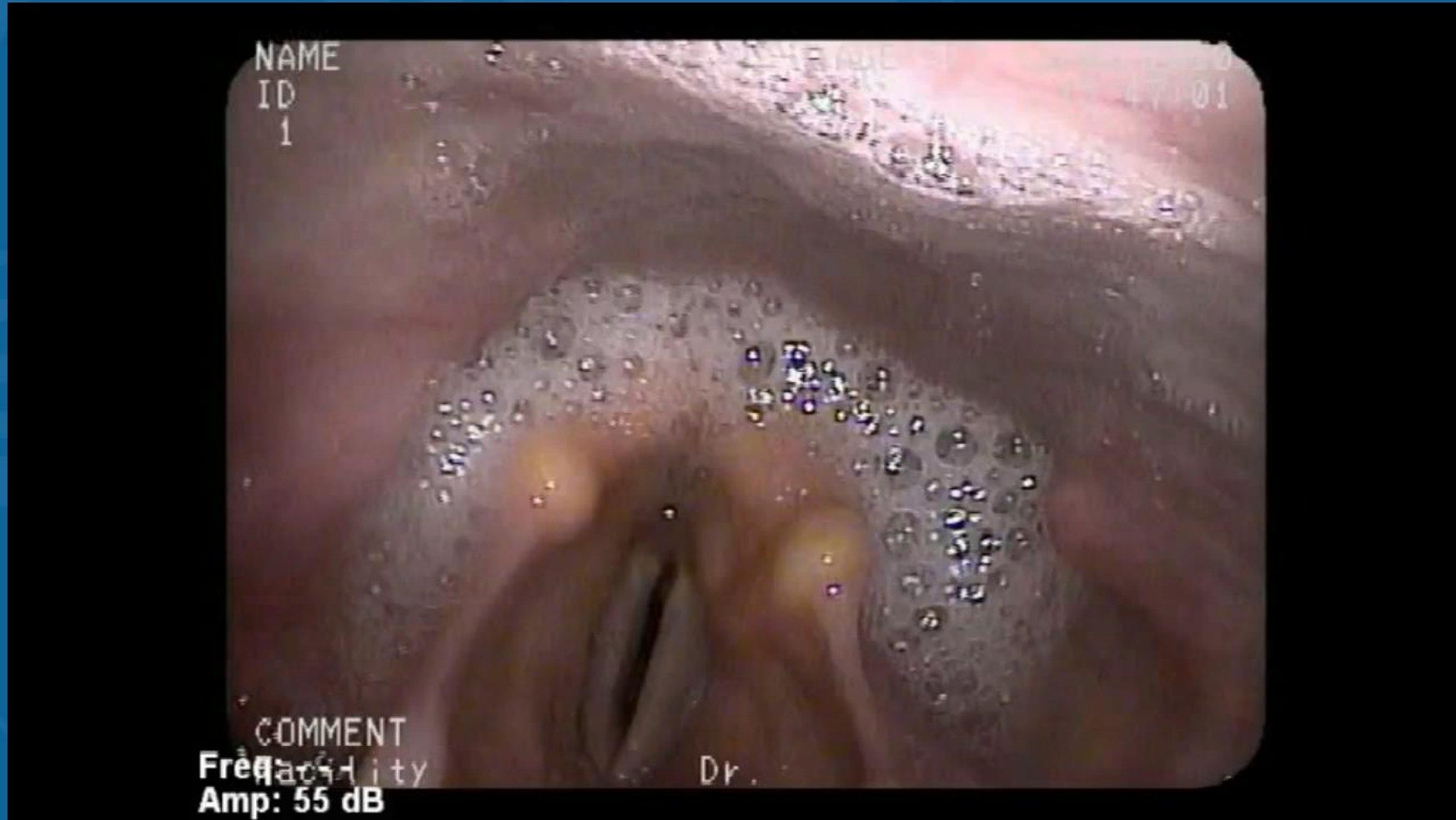Other Etiologies of Respiratory Noise

Glottic Stenosis

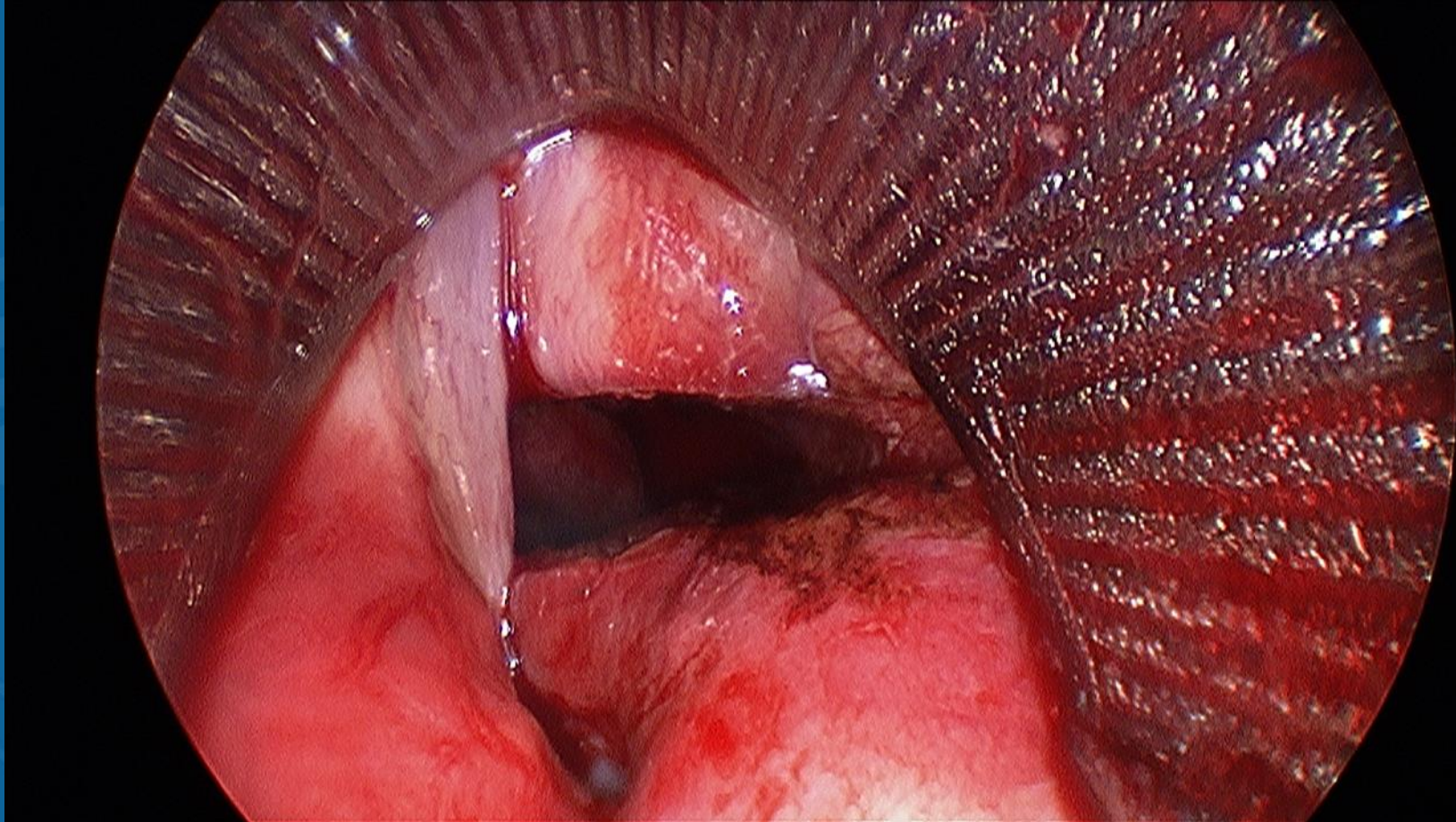
- Typically due to trauma causing scar or bilateral vocal fold paralysis
- Interarytenoid Scar
- Posterior Glottic Stenosis
- Treatment: Destructive (Sacrifice some voice for breathing)



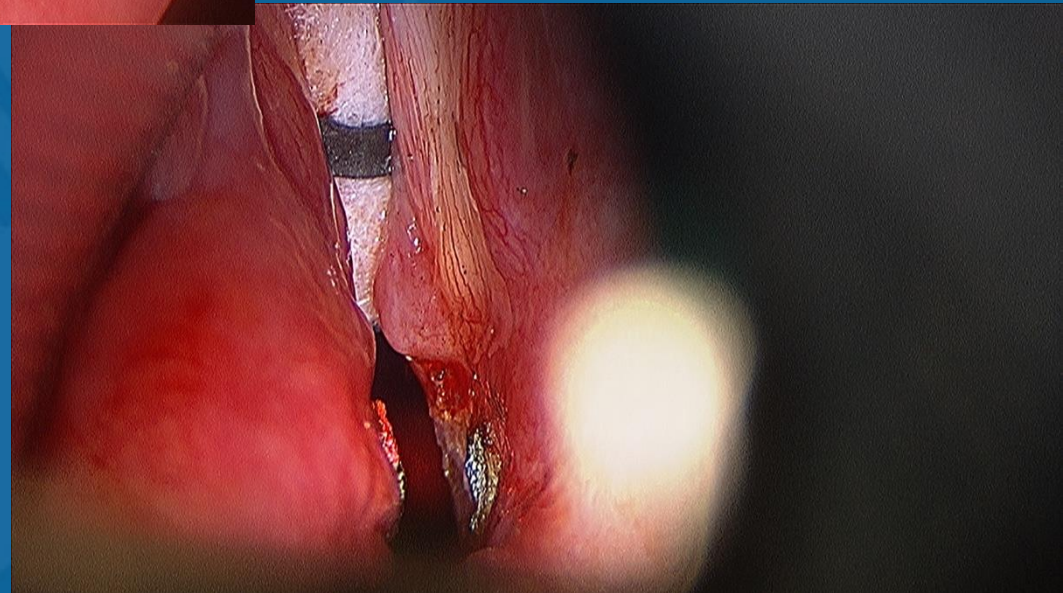
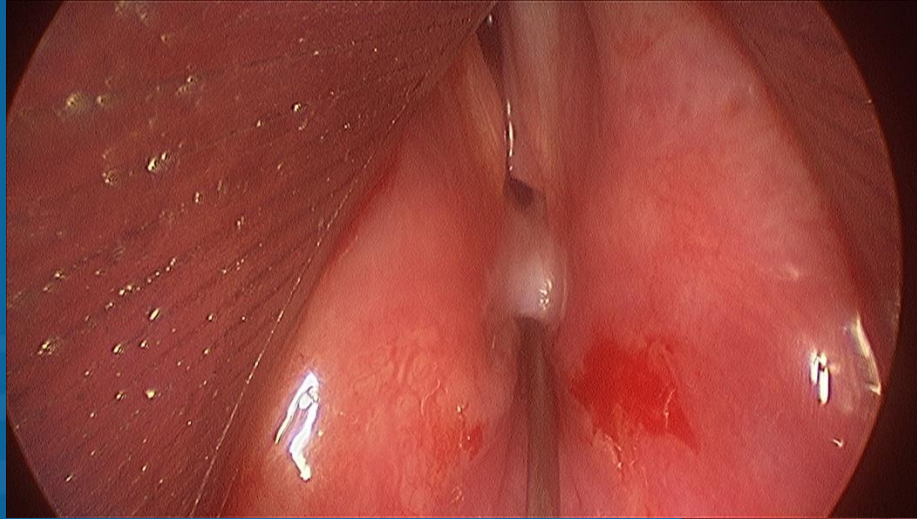
Pathology: Posterior Glottic Stenosis (PRE)



Pathology: Posterior Glottic Stenosis Often requires laser Cordotomy



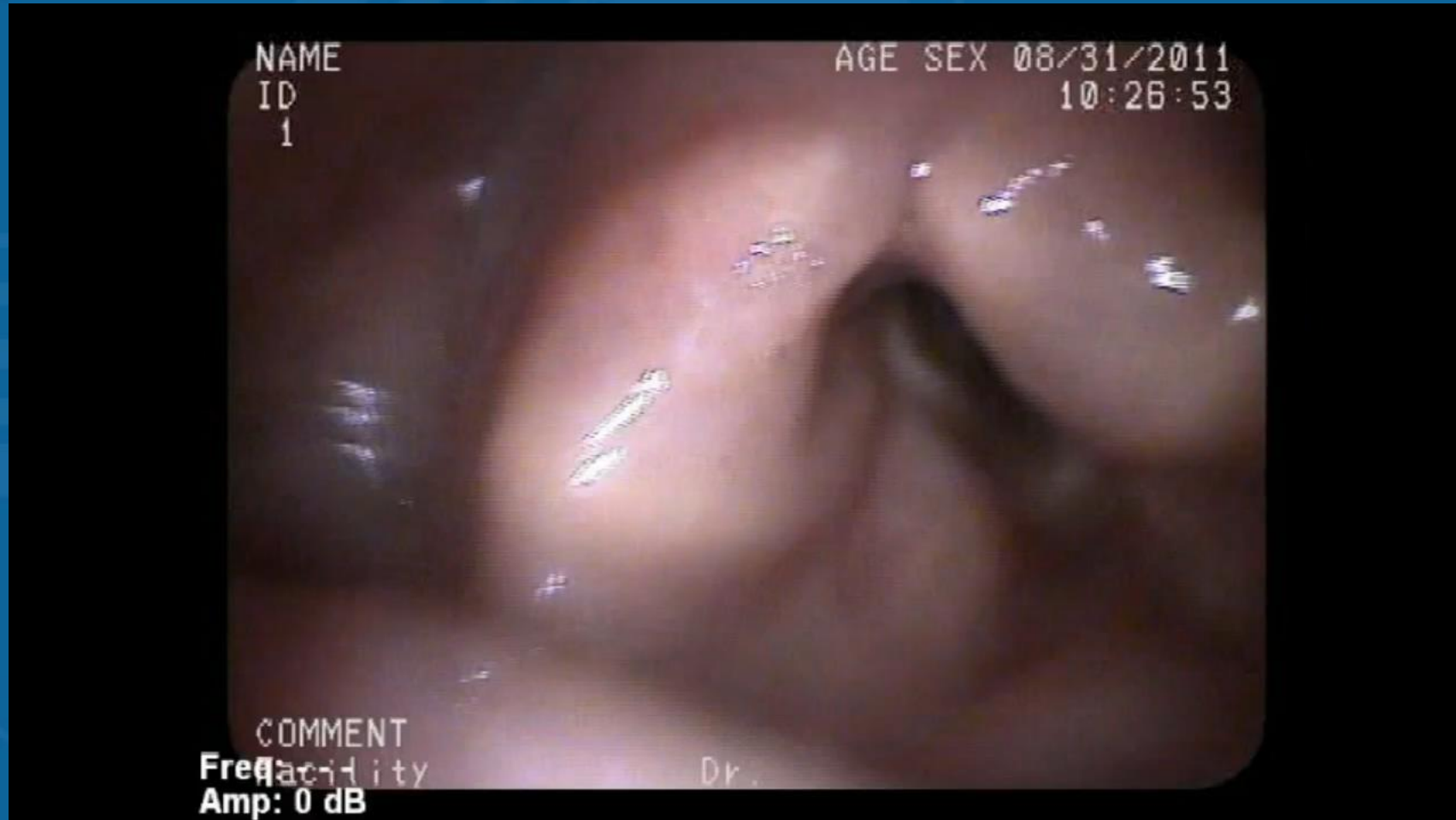Pathology: Posterior Glottic Stenosis (OR) But sometimes we are lucky..



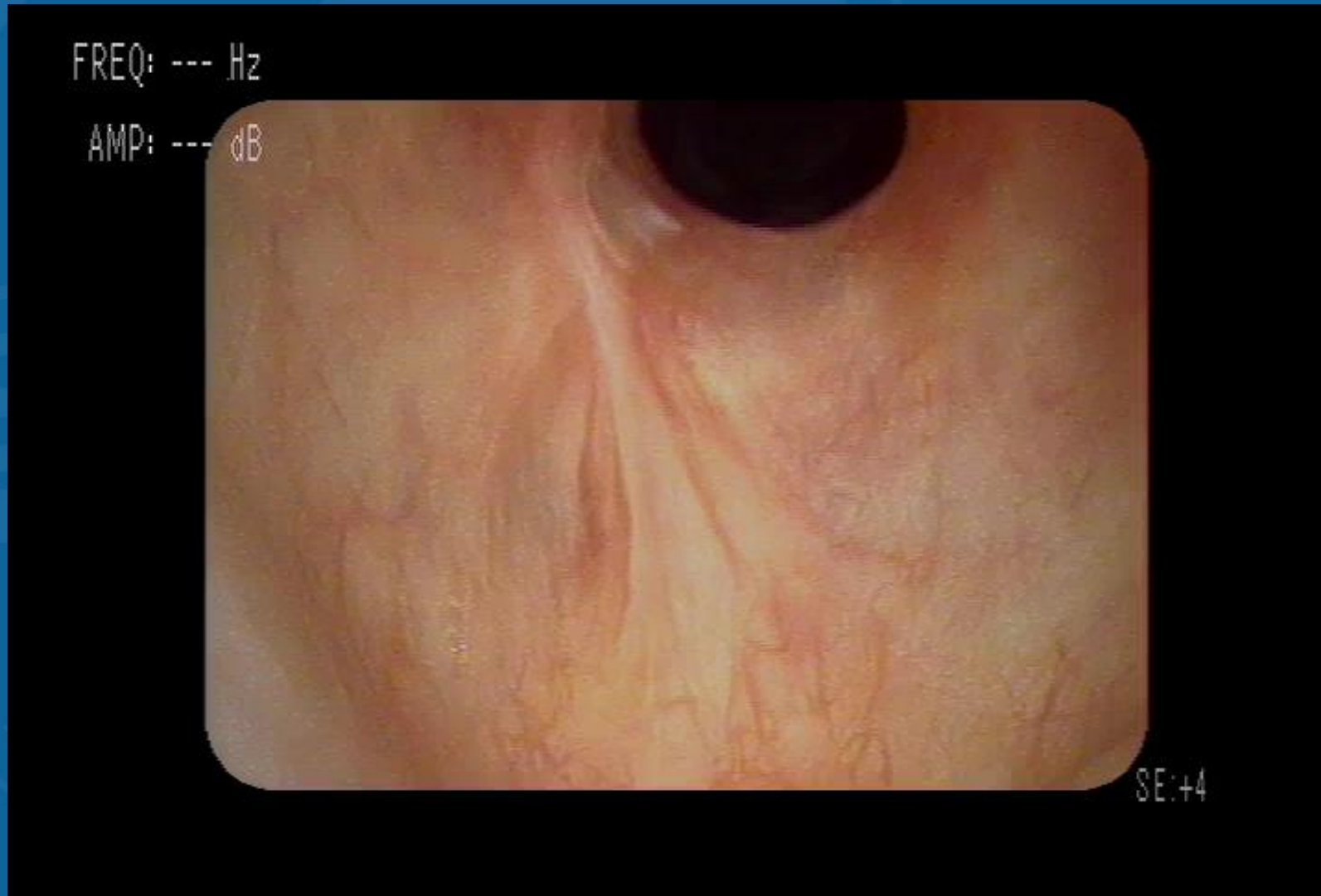Pathology: Posterior Glottic Stenosis (POST)



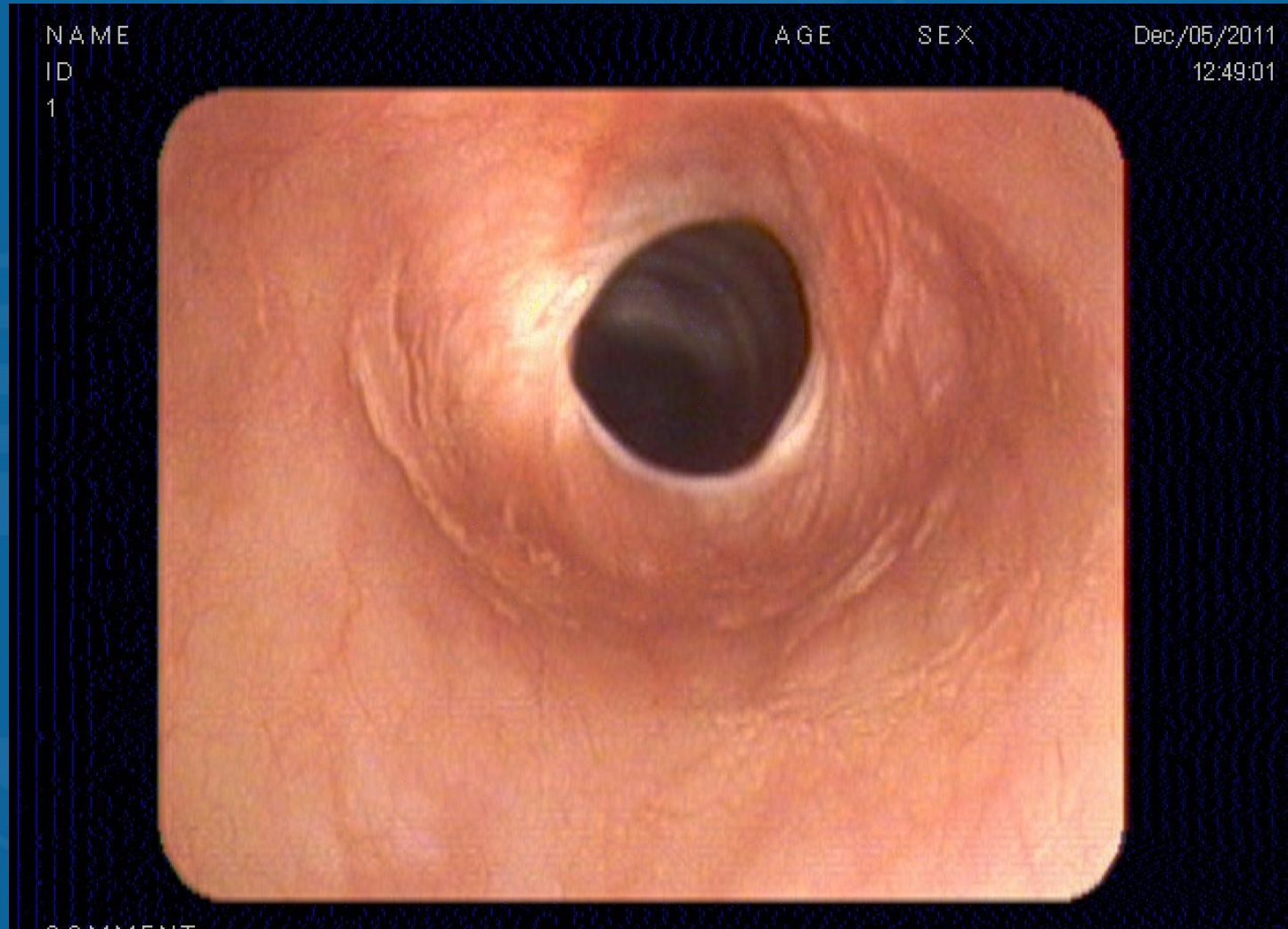
Evaluating the subglottis: awake tracheoscopy



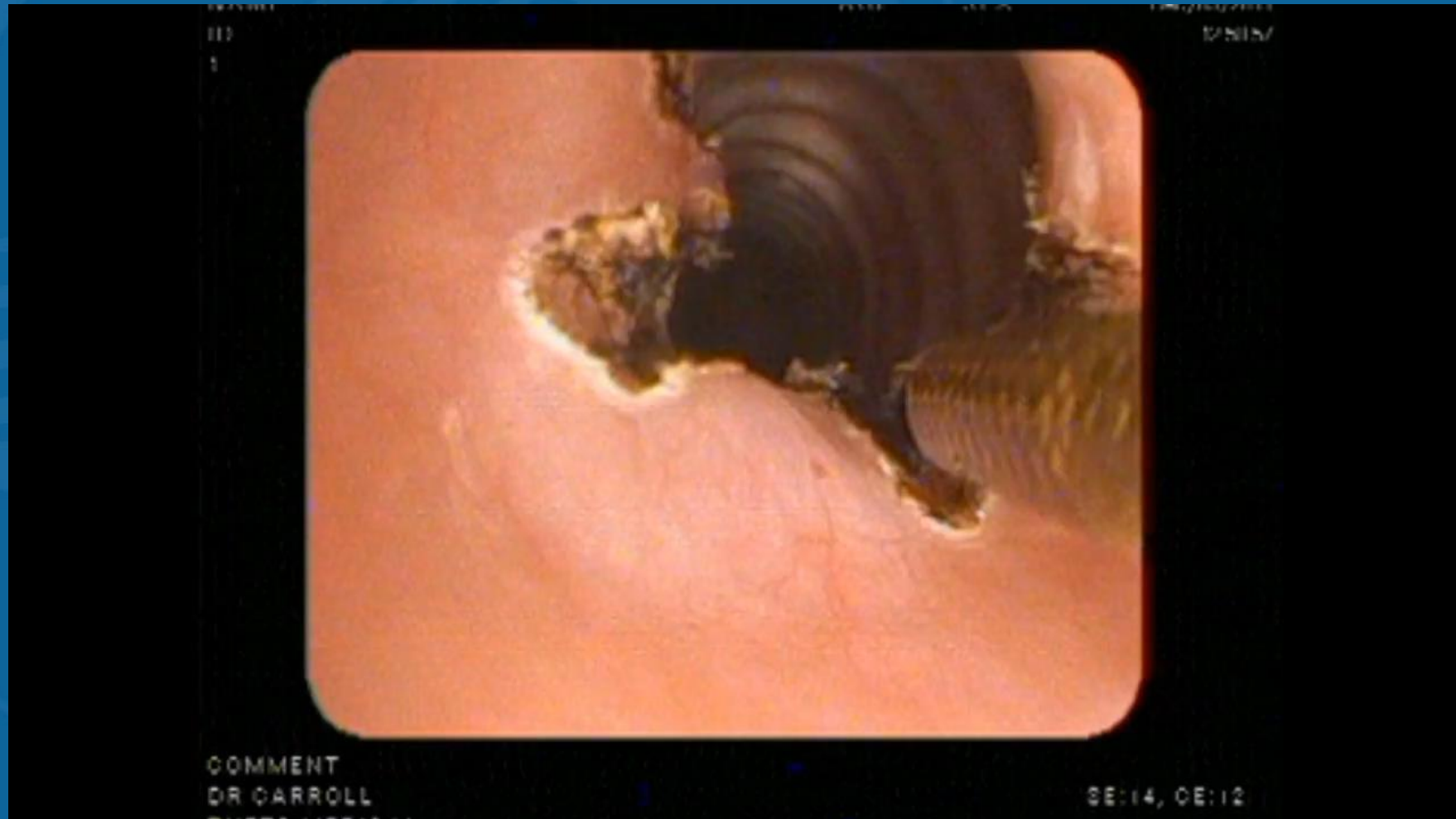
Pathology: Subglottic Stenosis with steroid injection



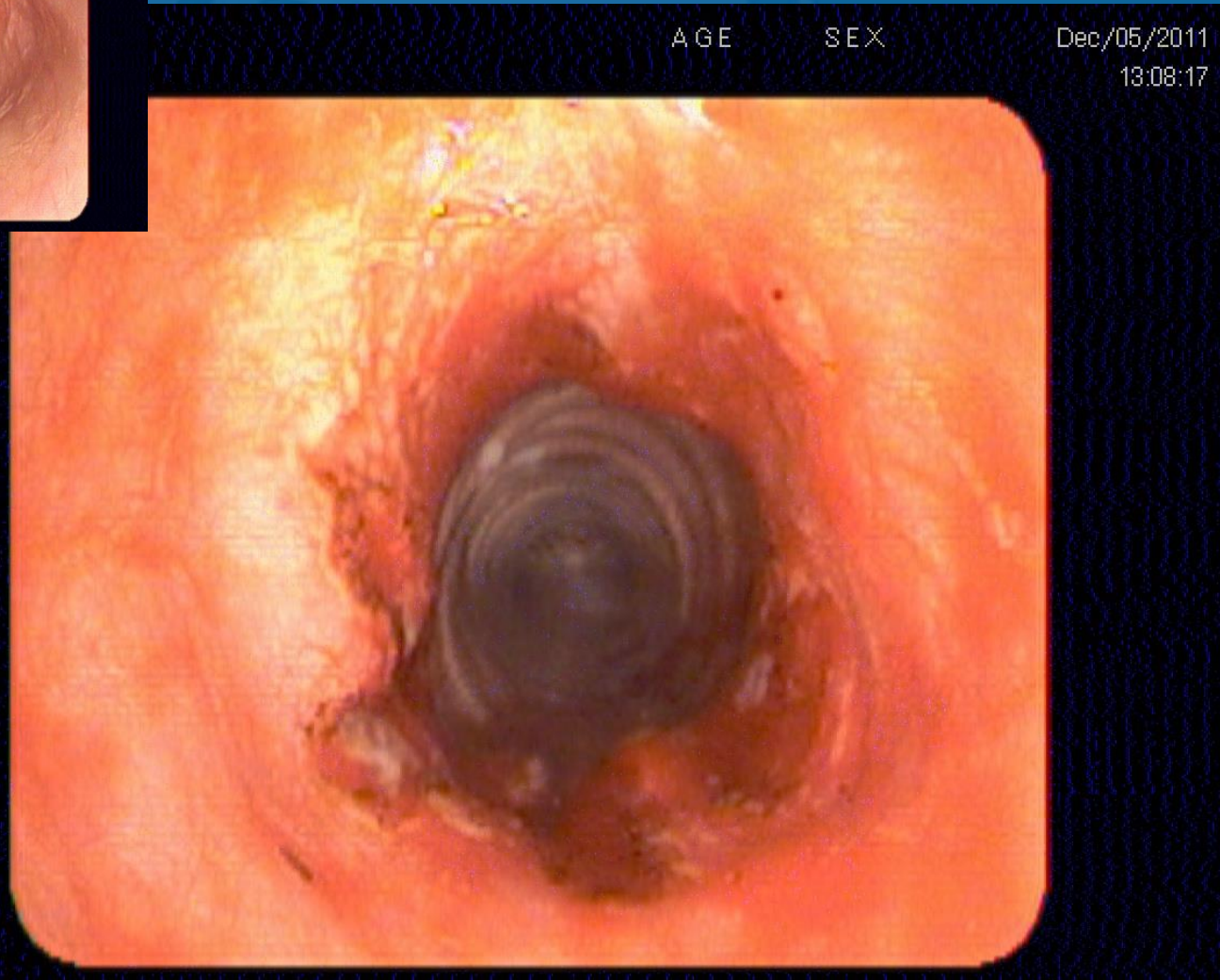
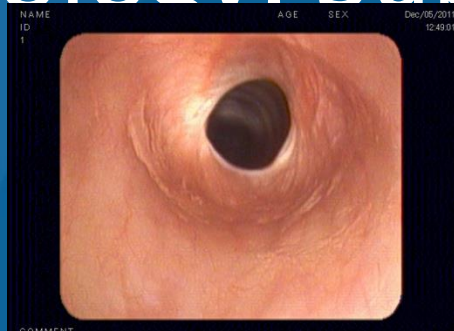Pathology: Subglottic Stenosis OR Management



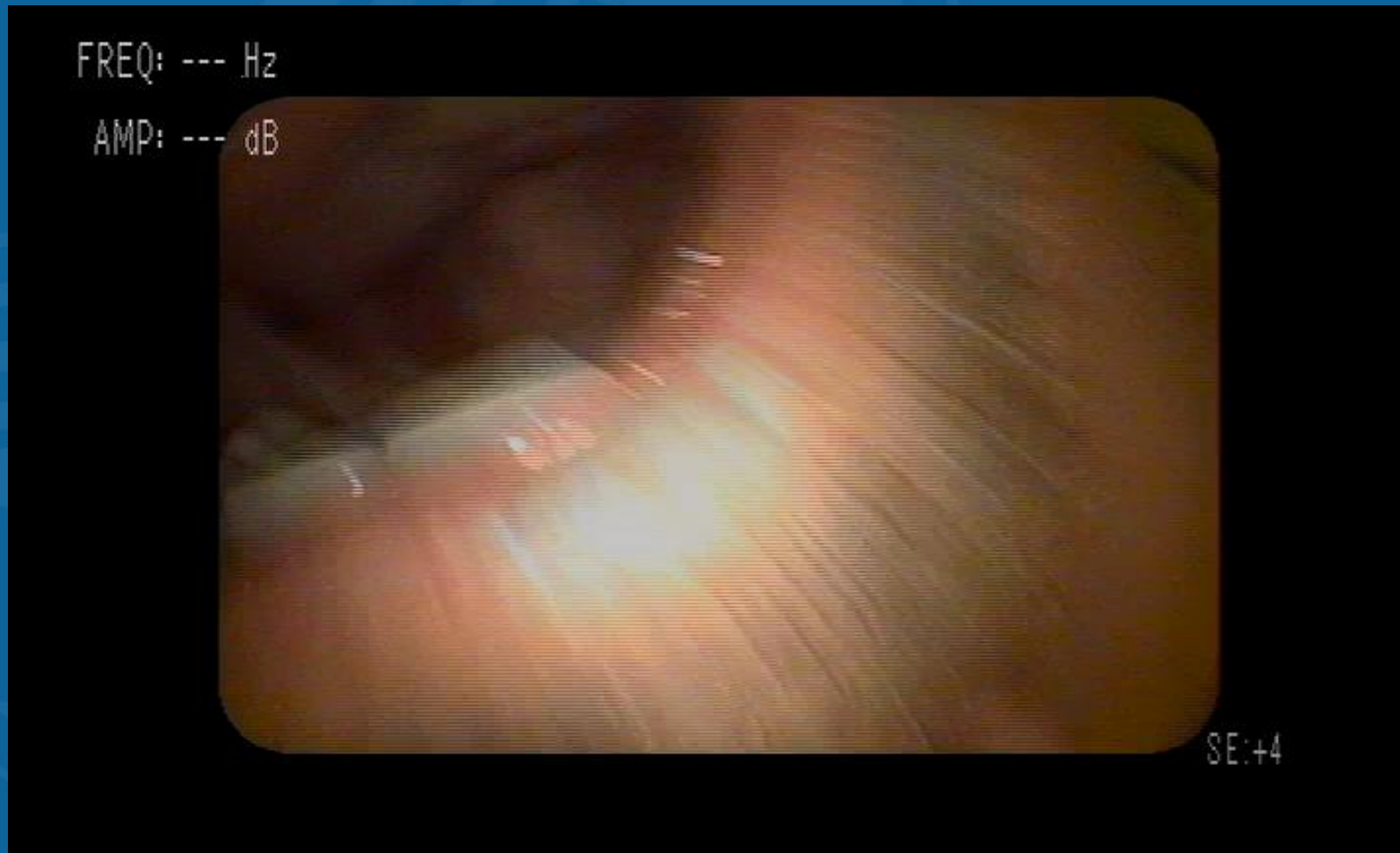Pathology: Subglottic Stenosis OR Management (Laser Then Balloon)



Pathology: Subglottic Stenosis OR Management



Pathology: Supraglottic Stenosis



Chronic Cough

- Allergic rhinitis/PND
 - Cough variant asthma
 - Reflux
- } These Three:
- Some now add Eosinophilic Bronchitis
 - Note that post viral/neurogenic cough is missing!?
 - Treatments for neurogenic cough can help *most* coughs but risks associated with reflux may be ignored
 - If you use this as first line, consider EGD

These Three:

- Etiology of 86% of CC in adults
- Etiology of 99% of CC if:
 - Immunocompetent
 - Nonsmoker with normal CXR
 - No history of ACE inhibitor use

Irwin et al, Chest 1998; 114(suppl 2):133S-184S

Pratter MR, Brightling CE, Boulet LP, Irwin RS. *Chest*. 2006;129(1):222S-231S.

How to approach reflux in LPR/Cough/ILO suspect patient...

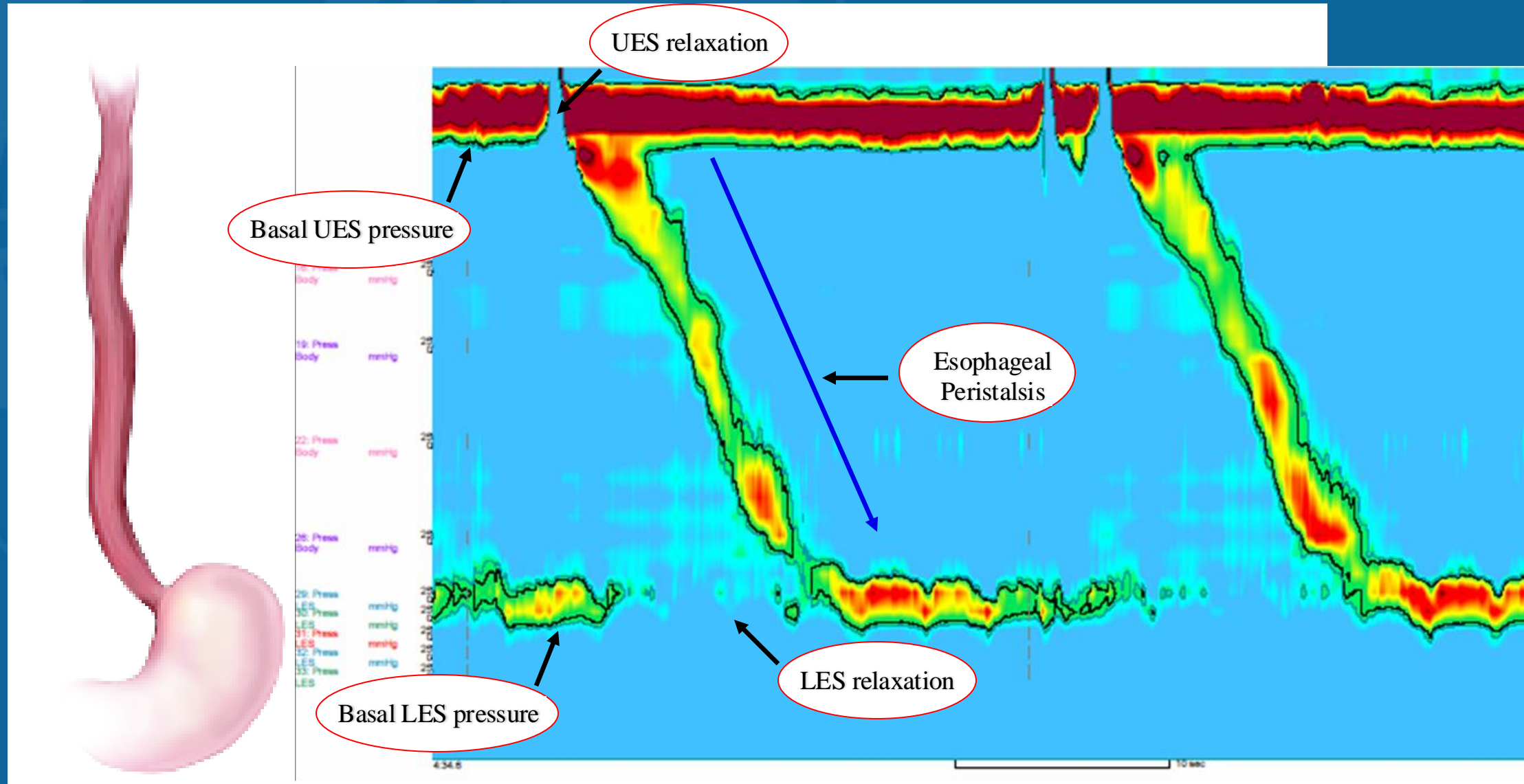
- Acid blocker trials DO NOT rule out reflux!!
 - Gastric liquid can still reflux
- It's time to consider reflux with Pepsin, not acid, as the problem
 - Proteolytic enzyme
 - Precursor pepsinogen is released by gastric chief cells
 - May play a role in the damage of epithelium related to GERD or LPR
 - Is it just a marker or part of pathophysiology of LPR?
 - Has been detected in saliva, trachea, lung, sinus, middle ear and exhaled breath condensate
- Key points
 - Avoid unnecessary PPIs
 - Interpret impedance for LPR differently than GERD
 - Esophageal dysmotility can cause Chronic Cough and increase reflux “symptoms”

-Perry KA et al. J Gastrointest Surg 2008

-Samuels TL and Johnston N. Otol Head Neck Surg 2009

-Wassenaar et al 2011

High-Resolution Manometry



Hypopharyngeal-esophageal multichannel intraluminal impedance and dual pH

“HEMII-pH” testing

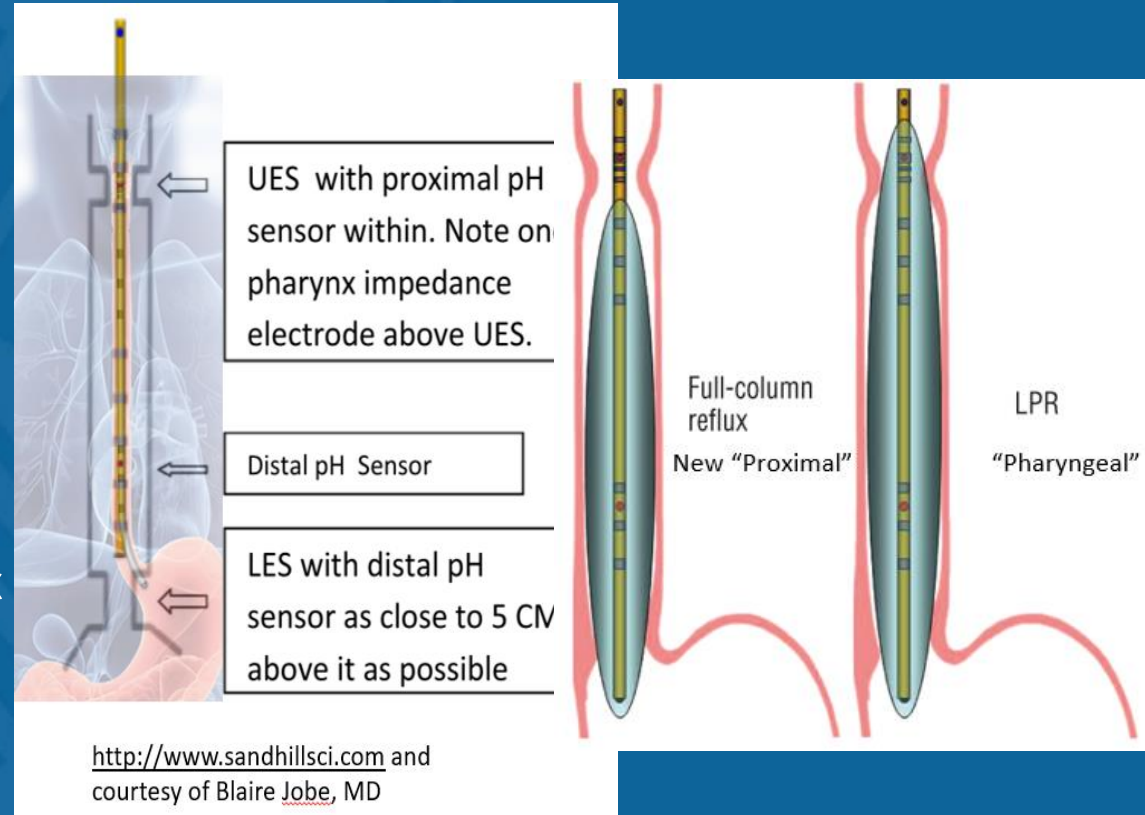
(aka ‘LPR’ Catheters)

Direct measurement of:

- Bolus movement, direction
- Bolus character (gas, liquid)
- Number of reflux events in 24hrs
- Proximal extent of liquid reflux “proximal” vs. “pharyngeal”

Detects reflux irrespective of pH

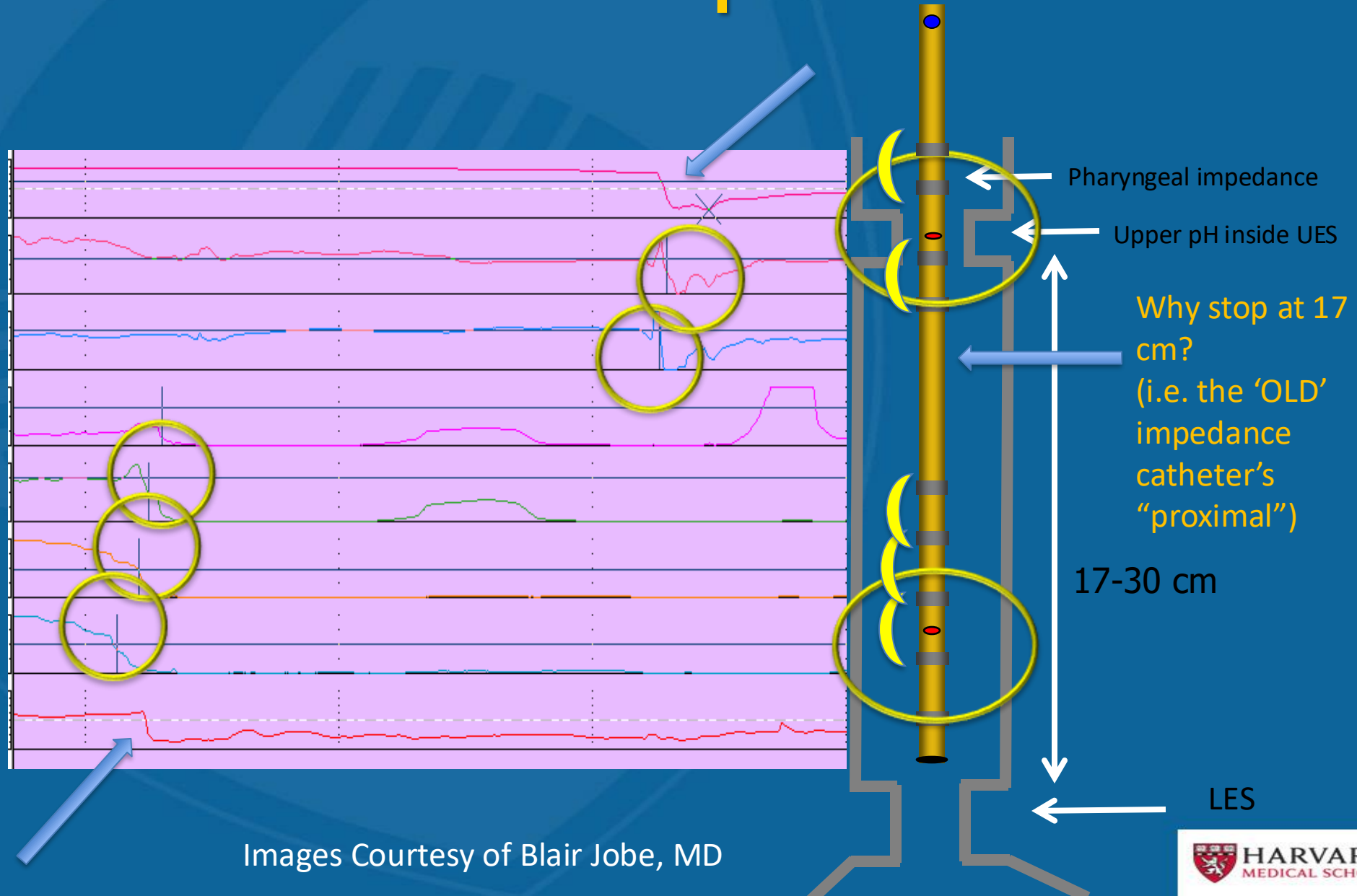
- Acid Vs. Non-Acid
- Upper and lower pH



- “Abnormal” if 1-2 or more pharyngeal impedance events
- 6-14 or more proximal events may be more specific to identifying abnormal LPR
- Is this pathologic?

- Hoppo T et al. JAMA Surgery 2011
- Sikvai DR, Cai JX, Leung R et al. J Gastroenterol Hepatol 2020

HEMII-pH



Images Courtesy of Blair Jobe, MD

The Symptom Dilemma

- **Most 'LPR' symptoms are not specific**
 - CC, throat clearing, globus sensation, excessive mucus, PND, dysphonia
- 90% of patients have overlapping etiologies
 - LPR, GERD, Allergy, Environmental Irritant, Smoking...Glottic Closure Pathology
- Treatment “failure” may be a partial success
 - There may be LPR present, but is it the only diagnosis contributing to your patient’s symptoms?

What Else Can Be Cause of Cough?

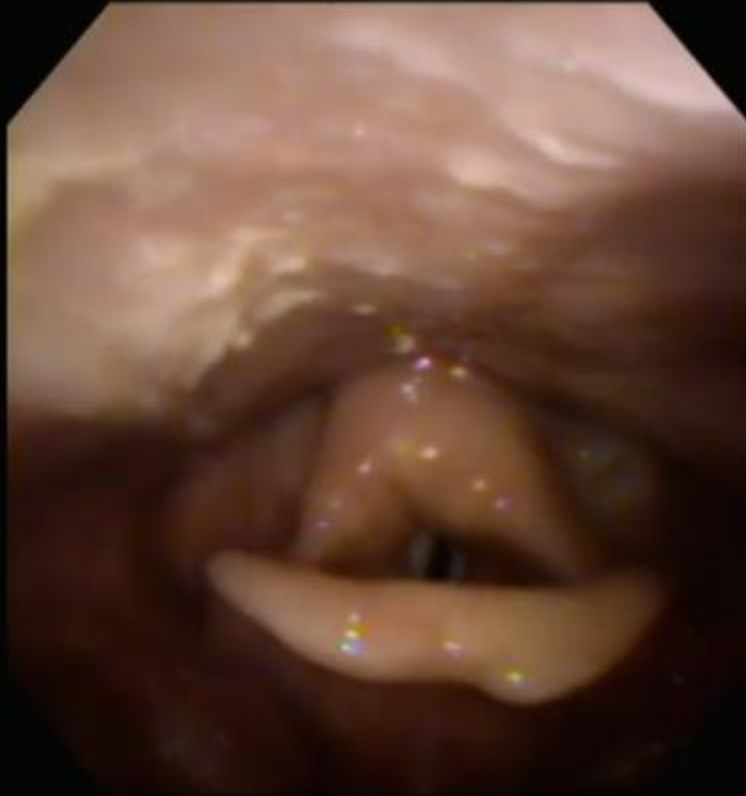Two of the most valuable questions for any laryngological complaint...

1. Does your cough (symptom) get worse as the day goes on?
2. Does talking/laughing trigger your cough?

Consider that the voice/glottic closure
is the etiology of the cough

- Glottic Insufficiency: The pathologic loss of air from the glottis during normal phonation

Pathology: Glottic Insufficiency



- Gross/Obvious:
 - True vocal fold (TVF) paralysis
 - Severe TVF atrophy
 - Cough due to inability to clear secretions or aspiration
 - Associated dysphonia
- Can be more subtle from aging or weakness (paresis)

Plan with new subtle GI patient

- Voice Pathologist decides if patient is a candidate
- Voice therapy first if 'stimulable':

If not a therapy candidate or fails to improve...

- **Diagnostic Vocal Fold Injection (DVFI)**
to improve quality of life (a 'Test Drive')
- Carboxymethylcellulose (CMC)
 - **MY PREFERRED DVFI MATERIAL**
- Per Oral Route—preferred due to perpendicular insertion

Conclusions

- ILO is best diagnosed when provoked and with laryngoscopy finding of >50% glottic closure
- For ILO and Cough: HEMII-pH and HRM testing can identify pharyngeal non-Acid events
 - Before acid suppression trials if possible
 - Stroboscopy in all comers (missed pathology and avenues for SLP/Doc treatments)
- Treat stenosis or glottic insufficiency (diagnostic injection augmentation)
- **Speech-Language Pathologists can help ILO and Cough patients!**

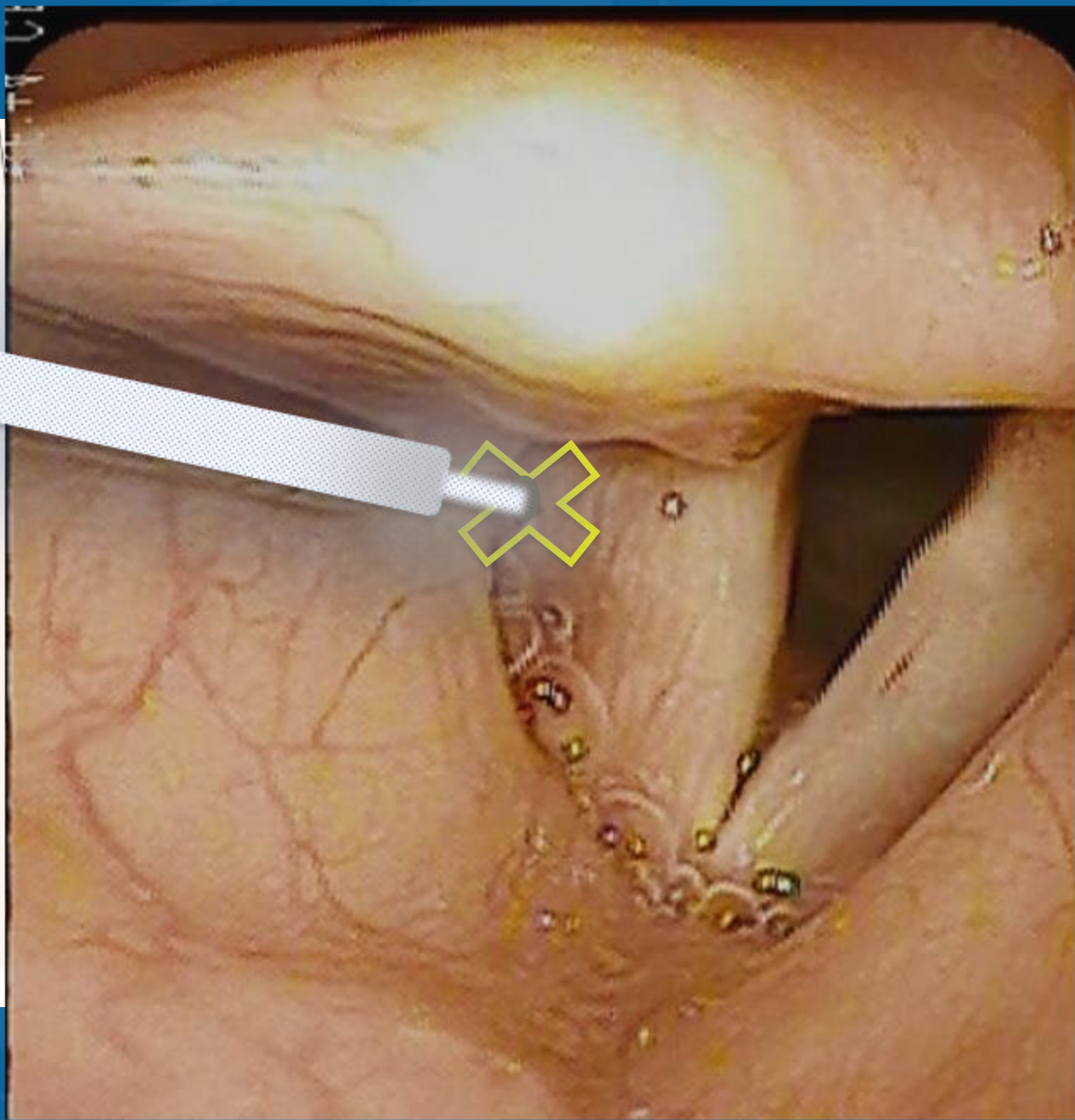
THANK YOU!

TCARROLL@BWH.HARVARD.EDU

LLGORDON@BWH.HARVARD.EDU

BWH VOICE PROGRAM:

617-525-3000



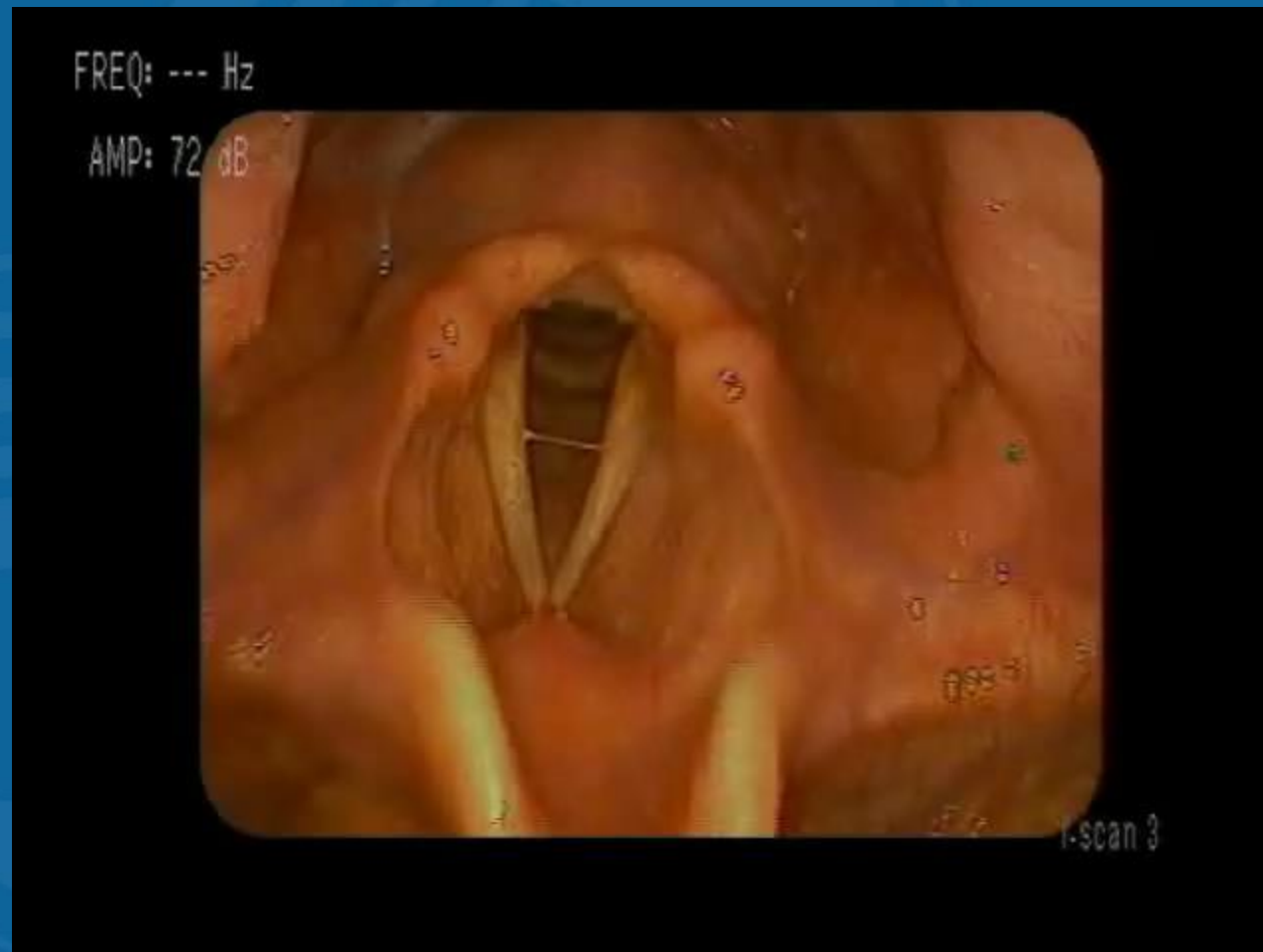
What to expect from DVFI?

- DVFI “Success” =
 - Patient report of specific throat symptom improvement (throat clear, globus etc.)
 - Evidence of improved phase closure on strobe
 - Carroll TL, Faudoa E, Van Doren M. Evaluation of a Shorter Follow-up Time to Capture Benefit of a Trial Vocal Fold Augmentation. *Journal of Voice*. 2019;33(2):169-175.
- Proceed to Lipoinjection (Fat) augmentation in OR
 - Vs. Office Injection Augmentation
 - Durable injection augmentation materials
 - Calcium Hydroxylapatite -- per oral or percutaneous
 - Silk/Hyaluronic Acid (Silk-HA) – transnasal catheter or percutaneous
 - Medialization laryngoplasty with Gore-Tex®


Case Cough and Atrophy

- 80 yo male with 2 years of chronic cough
- Works as foreman in construction
- Other complaints: Globus and hoarseness
- Talking stimulates cough
- Taking omeprazole 20 BID for 4 years
- VHI-10: 2
- RSI: 8 (circled 5 for cough)

Initial Flexible Stroboscopy




Trial Vocal Fold Augmentation



4 Weeks later

- Cough resolved
- Voice remained hoarse
- VHI-10: 3
- RSI: 2



What Changed?

- Improving glottal competence improved cough/tickle with phonation
- Why?
 - Less aperiodic vibration on initiation of phonation
 - Patient hears a better voice and brain doesn't think mucus is in the way and need to clear throat resolves